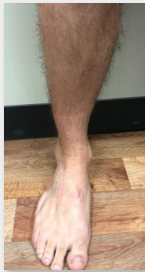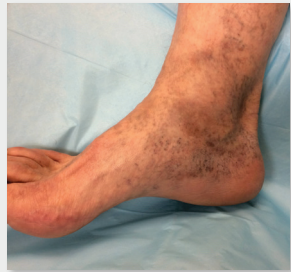


PHLEBOLYMPHEDEMA DISEASE PROGRESSION

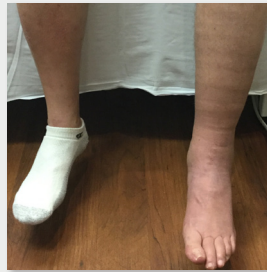CVI drives lymphatic damage and compromises local immune response^{1,2}



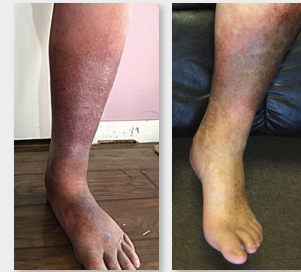- Healthy Veins



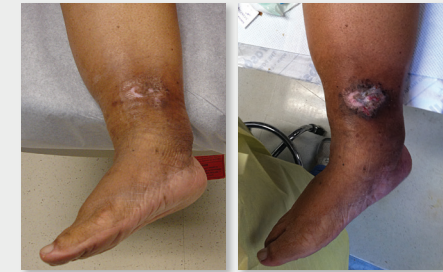- Venous Hypertension
- Increased Fluid Filtration



- Edema
- Stagnant Proteins
- Susceptible to Infection



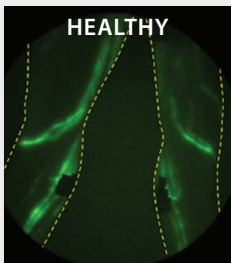
- Hyperpigmentation
- Eczema/Dermatitis
- Fibrosis



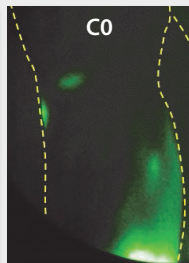
- Wounds
- Fat Deposition

Progressive and Irreversible Lymphatic Damage^{1,2,3}

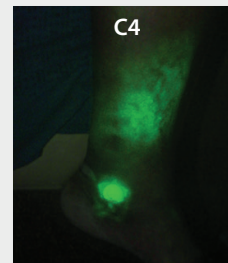
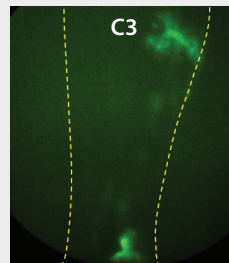
Compromised Immune Response^{1,2}



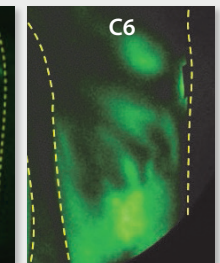
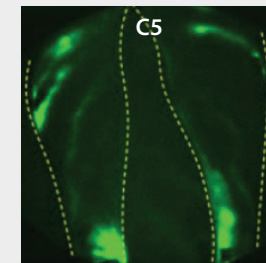
Normal lymph flow into lymphatic capillaries



Lymphatic backflow present without clinical symptoms



Lymphatic stasis corresponding to hemosiderin staining



Significant lymphatic backflow surrounding open wound

Lymphatic dysfunction shown through near infrared lymphatic imaging⁴

1. Ruocco E, et al. Phlebolymphe'dema: disregarded cause of immunocompromised district. *Clin Dermatol*. 2012 Sep-Oct;30(5):541-3. doi: 10.1016/j.clindermatol.2012.04.004.

2. Farrow W. Phlebolymphe'dema—A common underdiagnosed and undertreated problem in the wound care clinic. *The Journal of the American College of Certified Wound Specialists*. 2010;2(1):14-23.

3. Scelsi R, et al. Morphological changes of dermal blood and lymphatic vessels in chronic venous insufficiency of the leg. *Int Angiol*. 1994 Dec;13(4):308-11

4. Rasmussen JC, et al. Lymphatic transport in patients with chronic venous insufficiency and venous leg ulcers following sequential pneumatic compression. *J Vasc Surg: Venous Lymphat Disord*. 2016 Jan;4(1):9-17. doi: 10.1016/j.jvsv.2015.10.004.

Permission for use of patient images on file at Tactile Medical.